Nucl Med Mol Imaging
Vol. 41, No. 3, Jun 2007

Original Article

유방 SPECT 및 초음파 컴퓨터진단시스템 결합의 유방암 진단성능

가천의과학대학교 길병원 핵의학과[1], 서울대학교 의과대학 방사선과[2],
캐드임팩트(주)[3], 전남대학교병원 핵의학과[4], 가천의과학대학교 길병원 내과[5]
황경훈[1] · 이준구[2] · 김종효[2] · 이형지[3] · 엄경식[3] · 이병일[4] · 최덕주[5] · 최원식[1]

Diagnostic Performance of Combined Single Photon Emission Computed Tomographic Scintimammography and Ultrasonography Based on Computer-Aided Diagnosis for Breast Cancer

Kyung-Hoon Hwang, M.D.[1], Jun Gu Lee, M.D.[2], Jong Hyo Kim[2], Hyung-Ji Lee, M.D.[3], Kyong-Sik Om, M.D.[3], Byeong-Il Lee, M.D.[4], Duckjoo Choi[5], and Wonsick Choe, M.D.[1]

[1]Department of Nuclear Medicine, Gachon University Gil Medical Center, Incheon, Korea; [2]Department of Radiology, Seoul National University, College of Medicine, Seoul, Korea; [3]CAD Impact, Inc. Seoul, Korea; [4]Department of Nuclear Medicine, Chonnam National University Hospital, Gwangju, Korea; [5]Department of Internal Medicine, Gachon University Gil Medical Center, Incheon, Korea

Purpose: We investigated whether the diagnostic performance of SPECT scintimammography (SMM) can be improved by adding computer-aided diagnosis (CAD) of ultrasonography (US). **Materials and methods:** We reviewed breast SPECT SMM images and corresponding US images from 40 patients with breast masses (21 malignant and 19 benign tumors). The quantitative data of SPECT SMM were obtained as the uptake ratio of lesion to contralateral normal breast. The morphologic features of the breast lesions on US were extracted and quantitated using the automated CAD software program. The diagnostic performance of SPECT SMM and CAD of US alone was determined using receiver operating characteristic (ROC) curve analysis. The best discriminating parameter (D-value) combining SPECT SMM and the CAD of US was created. The sensitivity, specificity and accuracy of combined two diagnostic modalities were compared to those of a single one. **Results:** Both SPECT SMM and CAD of US showed a relatively good diagnostic performance (area under curve = 0.846 and 0.831, respectively). Combining the results of SPECT SMM and CAD of US resulted in improved diagnostic performance (area under curve =0.860), but there was no statistical differerence in sensitivity, specificity and accuracy between the combined method and a single modality. **Conclusion:** It seems that combining the results of SPECT SMM and CAD of breast US do not significantly improve the diagnostic performance for diagnosis of breast cancer, compared with that of SPECT SMM alone. However, SPECT SMM and CAD of US may complement each other in differential diagnosis of breast cancer. (Nucl Med Mol Imaging 2007;41(3):201-208)

Key Words: single photon emission computed tomography (SPECT), computer aided diagnosis (CAD), ultrasonography (US), scintimammography (SMM), breast cancer

Introduction

Breast cancer is the second in the prevalence rate of cancer among women in Korea[1)] and it has recently become the first in incidence rate. One out of nine women gets breast cancer during her lifetime in the developed countries.[2)]

Standard breast diagnosis is based on mammography and ultrasonography (US). Many lesions found turn out to

• **Received**: 2006. 11. 14. • **Accepted**: 2007. 4. 23.
• Address for reprints: Duckjoo Choi, Department of Internal Medicine, Gachon University Gil Medical Certer, 1198 Guwol-dong, Namdong-gu, Incheon 405-760, Korea
Te.: 82-32-460-8374, Fax: 82-32-460-3408
E-mail: djc@gilhospital.com
※This work was financially supported by grant from the Gachon University Research Fund.

Table 1. Age and Histologic Diagnosis of Study Populations

	Malignant	Benign	Total
Number	21	19	40
Age (Years)	49.8±9.9	38.3±9.6	44.3±11.2
Histology	IDC (20) DCIS† (1)	Fibroadenoma (6) Fibrocystic disease (5) Phylloides tumor (1) Granuloma (1)	
F/U Confirm		(6)	

*IDC: invasive ductal carcinoma
† DCIS: ductal carcinoma in situ

be benign up to about 70~85%. US is known to provide radiologists with an ability to better differentiate benign lesions from malignant ones that may be suggestive of cancer. However, mammography is characterized by a low specificity and a low positive predictability.[3] US can only slightly increase the specificity and is operator-dependent. Single Photon Emission Computed Tomographic (SPECT) Scintimammography (SMM) using radio-pharmaceuticals shows the overall high diagnostic accuracy, but it has a limitation in spatial resolution for small lesions.[4] Recently, in order to minimize the effect of the operator-dependent nature inherent in US, many computerized approaches have been performed to differentiate between benign and malignant breast lesions.[5,6]

We applied new US computer-aided diagnosis (CAD) algorithm for breast mass to provide the likelihood of malignancy and investigated whether the diagnostic performance of SPECT SMM can be improved by adding this CAD analysis of US.

Materials and Methods

1. Patients

A total of 40 SPECT SMM images and corresponding breast US images from 40 patients presented with breast masses (21 malignant and 19 benign tumors) were investigated (mean age of 44.3 year, range 17-72 ; Table 1). Diagnosis was confirmed by histopathology or clinical follow-up of more than 12 months (Table 1).

2. SMM acquisition

SMM was obtained using ^{99m}Tc-tetrofosmin as planar and SPECT images. Five minutes after injection of 1,110MBq of ^{99m}Tc-tetrofosmin, prone lateral, supine anterior planar scans and supine SPECT were performed (MULTISPECT2, Siemens, Erlangen, Germany). Planar images were acquired with a 128×128 matrix size, an acquisition time of 5 minutes per view and a zoom factor of 1.45. SPECT images were acquired with a 128×128 matrix size, 90 projection frames and an acquisition time of 20 seconds per projection. Reconstruction was done using Butterworth filter (cut-off: 0.38, order: 1). From the SPECT images (Fig. 1), the uptake ratio of the lesion to the contralateral normal breast tissue (L/N ratio) was calculated using the same-sized rectangular ROI (region of interest) on the transverse image **and the uptake in the mid chest wall was used for the reference of normal breast uptake** (Fig. 2).



Fig. 1. Tc-99m tetrofosmin SPECT SMM shows a focal increased uptake in breast cancer (arrow).

3. Breast ultrasonography

US was performed for the breast lesion and contralateral

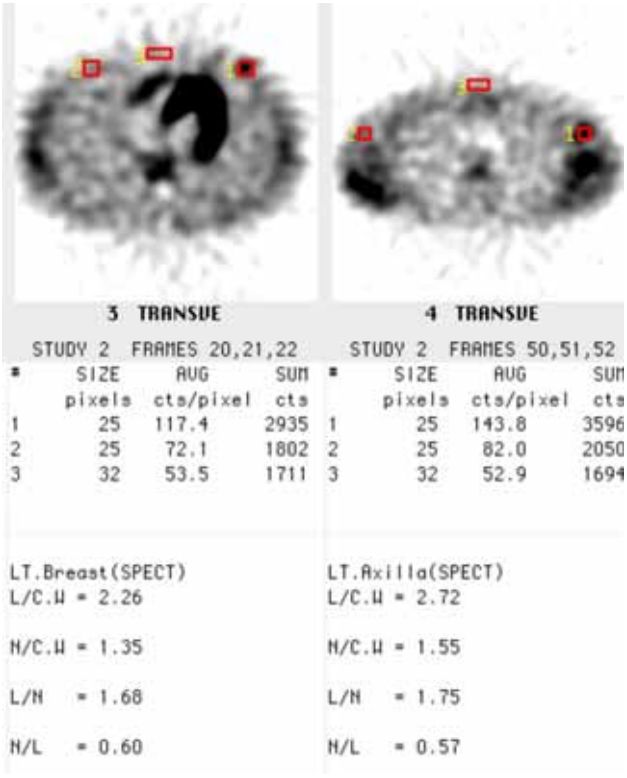

Fig. 2. The uptake ratio of the lesion to the contralateral normal breast tissue (L/N ratio was calculated using the same-sized rectangular ROI on the transverse image of SPECT SMM. (ROI1: breast lesion, ROI2: contralateral normal breast tissue and ROI3: mid chest wall for reference)

breast using US instrument with 5-10 MHz linear probe (ATL HDI-3000, Massachusetts, USA). The acquired images were digitalized to DICOM images and stored on PACS.

4. CAD method

We used commercially developed breast CAD software SonoEye (CAD Impact, Inc) to determine the likelihood of malignancy for US.

1) ROI (region of interest) selection on US

On US, the ROI was selected in minimum rectangular shape to contact the boundary of breast mass (Fig. 3).

2) Decision support by similar-cases retrieval on breast US

In the preprocessing stage, median and homomorphic filtering were used for noise reduction and order statistic filtering was used for image enhancement.[7] After that, Otsu thresholding was applied for the lesion segmentation.[8]

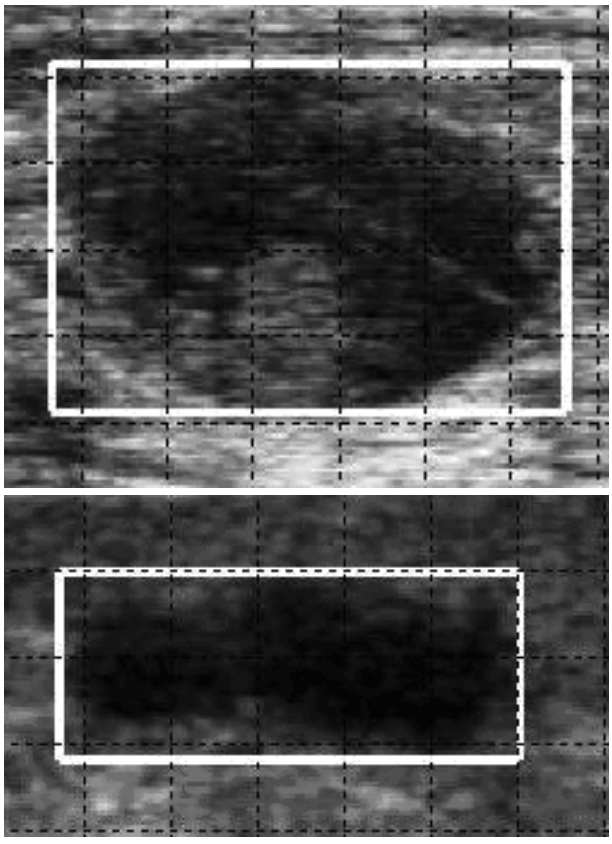

Fig. 3. ROI was selected as a minimal rectangle on breast US.

The algorithm used a breast ultrasound image retrieval system for the decision support of classification of breast lesions on US. Biopsy-proven direct-digital 1,034 data were used to construct the main database (DB) engine and the image database was constructed by 1,034 cases (Malignant cases are 411. Benign cases are 623). All of the cases were biopsy-proven. Two kinds of retrieval images of full size image and ROI image were executed.

Computer-generated malignant likelihood was calculated based on the retrieved images in the range from 0 to 1.0 (1.0: highly suggestive of malignancy, 0: lowly suggestive of malignancy).

3) Analysis algorithm

CAD algorithm used shape-emphasized features and texture-emphasized features. Shaped-emphasized features were characterized by a depth-to-width ratio and Hu moment.[9] Texture-emphasized features related to echo-pattern and margin were characterized by relative variance ratios computed from various regions dividing ROI.[10]

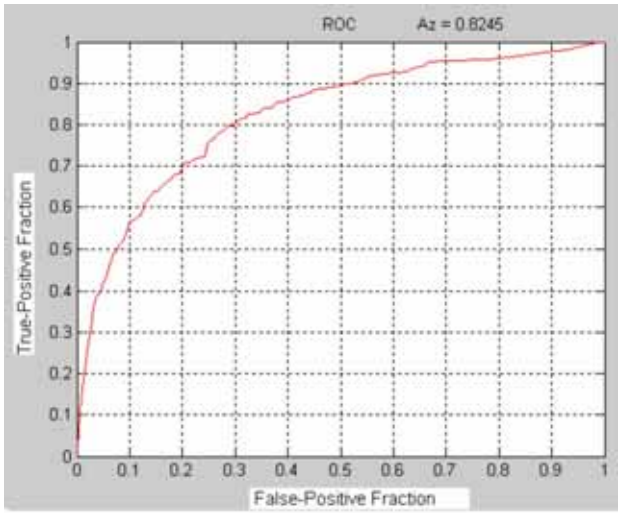

(Area under curve = 0.82)

Fig. 4. ROC analysis of CAD of US algorithm trained for 1,034 cases was done.

These sonographic features were merged through order statistic filtering analysis to yield an estimate of the final malignant score. The above algorithms were trained for 1,034 cases (Fig. 4) and proved to be robust to brightness and contrast.[10]

5. Quantitative analysis and combination of the results of SPECT SMM and CAD of US

The results of SPECT SMM were expressed as L/N ratio and those of CAD of US as percentage of malignancy likelihood. Receiver operating characteristic (ROC) curve analyses were performed to determine the optimal cut-off values of L/N ratio (SPECT SMM) and malignancy likelihood percentage (CAD of US), based on the confirmed diagnosis for the breast lesions (MedCalc version 6.0). The sensitivity, specificity and accuracy of SPECT SMM and CAD of US were determined from these optimal cut-off values from ROC curve analyses. The best discriminating new parameter (D-value) combining the SPECT SMM uptake value and the CAD results of US was created using linear discriminant analysis (SPSS version 10.0 for windows, SPSS inc.). The sensitivity, specificity and accuracy of were also calculated for this D-value and compared to those of SPECT SMM and CAD of US alone using McNemar's χ^2-test. Statistical significance was established at a p-value of <0.05.

Results

Results according to the breast mass size are depicted on Table 2. SPECT SMM seems to show a limitation for small breast lesions less than 1 cm. SPECT SMM and CAD of US demonstrated high diagnostic agreement (94%) in negative-confirmed cases, however, in positive-confirmed cases, they showed disagreement in 43% of cases (Table 3).

Table 2. Breast Mass Sizes and Imaging Results

Brest mass size	No. of cases	SPECT SMM	CAD of US
< 1 cm	7	Sen* (1/2), Spe† (5/5)	Sen (2/2), Spe (5/5)
1~2 cm	17	Sen (7/10), Spe (7/7)	Sen (7/10), Spe (7/7)
2~3 cm	8	Sen (4/6), Spe (2/2)	Sen (4/6), Spe (2/2)
> 3 cm	6	Sen (3/3), Spe (1/3)	Sen (1/3), Spe (1/3)

Size information was not available in 2 cases. Average size of overall, malignant and benign breast masses: 2.1 cm
*Sen: sensitivity
† Spe: specificity

Table 3. Diagnostic Agreement between SPECT SMM and CAD of US

		CAD of US	
		Positive	Negative
SPECT SMM	Positive	10*/ 2†	5 / 1
	Negative	4 / 0	2 / 16

*Number of Positive-confirmed cases / † Number of Negative-confirmed cases

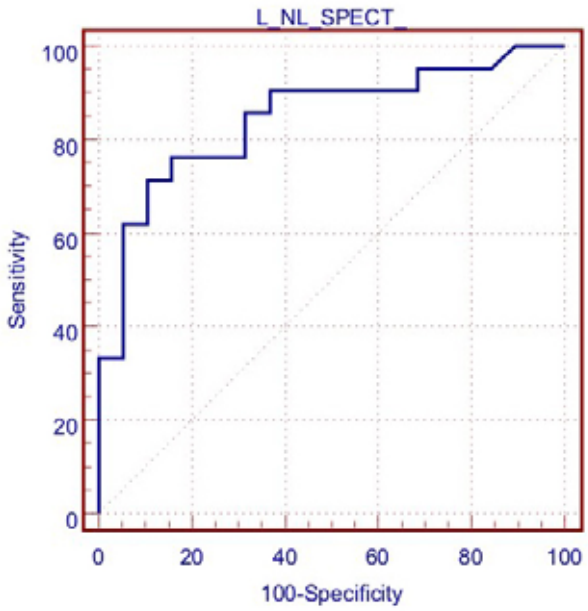

(Area under curve=0.846)

Fig. 5. ROC analysis of SPECT SMM showed a good diagnostic performance.

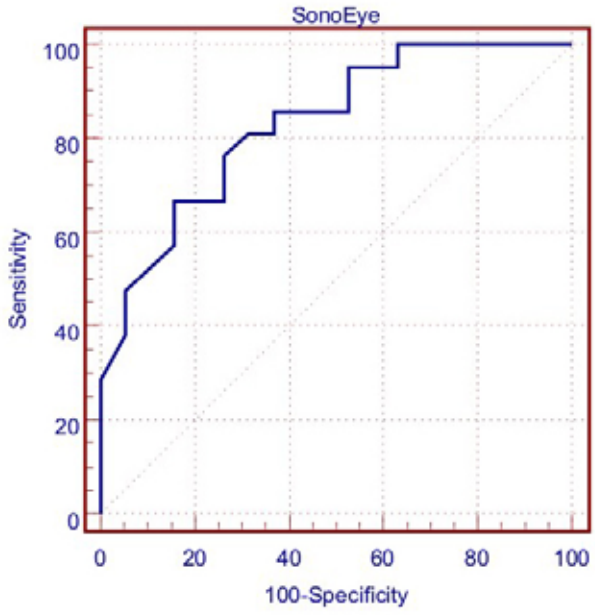

(Area under curve=0.831)

Fig. 6. ROC analysis of CAD of US also demonstrated a good diagnostic performance.

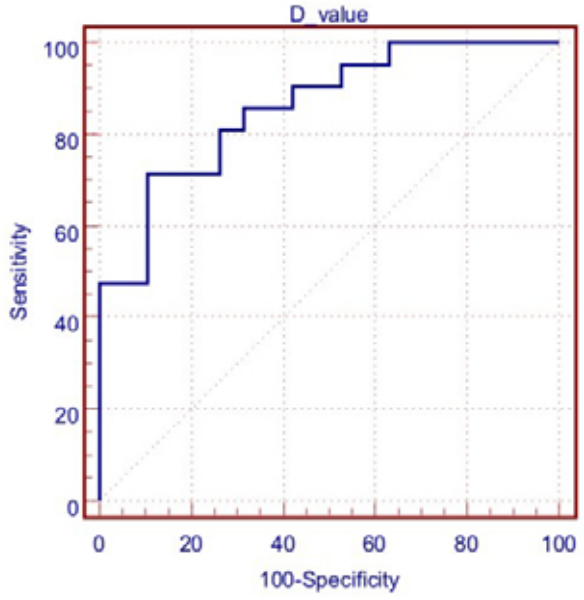

(Area under curve=0.860).

Fig. 7. ROC analysis of combining SPECT SMM and CAD of US revealed better diagnostic performance

Ninty percent of positive-confirmed cases were positive on either of them. Both SPECT SMM and CAD of US showed a relatively good diagnostic accuracy (area under curve=0.846 and 0.831; Fig. 5 and Fig. 6). The best discriminating formula combining the SPECT SMM value and the results of CAD of US was obtained as follows: D-value=0.559 L/N ratio (SMM) + 0.706 Malignancy Likelihood (CAD of US). Combining SPECT SMM and CAD of US also resulted in a good diagnostic accuracy (area under curve=0.860; Fig. 7). The distribution of each parameters in breast lesions was displayed according to the imaging methods (Fig. 8).

The optimal cut-off values of L/N ratio on SPECT SMM, malignancy likelihood on CAD of US and D-value were 2.02, 0.82 and 0.6843, respectively from ROC curve. In sensitivity, specificity and accuracy determined from the optimal cut-off values, there was no statistically significant differerence between combined SPECT/US and US alone, and no difference between SPECT/US and SPECT only for diagnosis of breast cancer (Table 4).

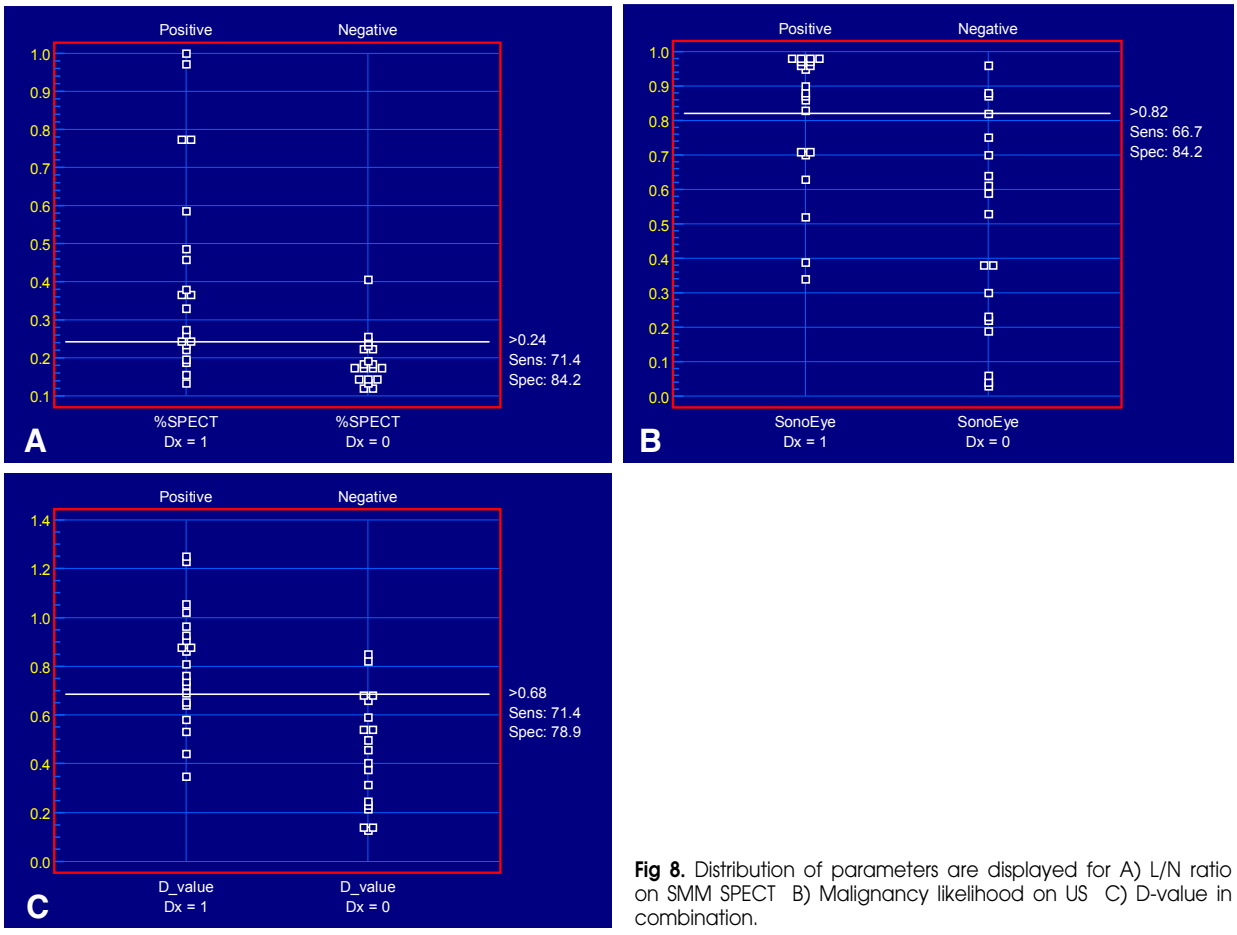

Fig 8. Distribution of parameters are displayed for A) L/N ratio on SMM SPECT B) Malignancy likelihood on US C) D-value in combination.

Table 4. Overall Diagnostic Accuracy

Diagnostic method	Sensitivity (%)	Specificity (%)	Accuracy (%)	Area under curve (ROC curve)
SPECT SMM	71	89	80	0.846
CAD of US	67	84	75	0.831
Combined SPECT+US	71	89	80	0.860
p-value	N.S.*	N.S.	N.S.	

*N.S.: not significant

Discussion

In the evaluation of breast lesions, detection and diagnosis are the most important steps. Breast US is routinely used as an adjunct to help to differentiate benign from malignant lesions. However, the overall accuracy of US in the diagnosis of breast cancer is not high enough.[11]

Recently, CAD has become one of the major research subjects in medical imaging and diagnostic radiology.[12,13] There have been many attempts to apply various CAD algorithms to differentiating between benign and malignant breast nodules. Although the idea of CAD application is promising, the results have been variable depending on the study population and the used algorithms.[14,15] There are possibilities of overlapped region of benign and malignant characteristics in the lesion morphology and the US images are partly operator-dependent.

Tc-99m tetrofosmin has been known to accumulate in various tumors and used to differentiate malignant from benign breast nodules with high specificity.[16,17] Therefore,

we expected better diagnostic performance combining the results of breast CAD of US (morphological analysis) and SMM using Tc-99m tetrofosmin (functional analysis).

The results of SMM and CAD of US alone showed fair diagnostic accuracy and the suggested methods using special features extracted from two modalities improved diagnostic performance in this study. However, statistical results were not significant, and it is probably because most false CAD negative breast cancers shows low to intermediate Tc-99m tetrofosmin uptake on SMM and vice versa. Therefore, combining SPECT SMM and CAD of US using linear discriminant analysis could not improve differential power in these lesions of intermediate gray zone. Improvement of diagnostic performance by combining SMM and mammography is variable in other reports.[18,19]

There are some limitations in this study. First, Tc-99m tetrofosmin uptake depends on the tumor pathology; however, further detailed pathologic correlation was not performed. Second, because the study population was relatively small, the comparison using area under the ROC curve could not be done. Thus, further study including more population is recommended. Third, only linear discriminant analysis was used to combine the results of SMM and those of CAD of US. A variety of update analysis tools such as SVM (support vector machine), ANN (artificial neural network), and Bayesian neural network[20] methods were not fully used in our study. Texture-emphasized features and shape-emphasized features are known to be helpful to classify benign and malignant tumor on US and it is possible to obtain better results using other methods for combining two results. Finally, the two-dimensional US display is incomplete in describing the nodule morphology. Thus, future study should use the three-dimensional US images of breast nodules including volume parameters, clinical features from electronic medical records (EMR) and more advanced nuclear medicine devices such as positron emission tomography.

In conclusion, the diagnostic performance of SMM in the differential diagnosis of the breast mass was not significantly improved by adding CAD of breast US. However, SMM and CAD of US may complement each other in differential diagnosis of breast cancer. Further studies including a larger population with more advanced imaging technology and analysis tools would be needed.

요 약

목적: 유방암의 감별진단에서 기존의 유방 초음파 검사나 핵의학 유방SPECT의 진단성능에는 한계가 있다. 저자들은 초음파 컴퓨터진단시스템(CAD: computer aided diagnosis)의 적용에 의하여 유방 SPECT의 진단성능이 향상되는지를 알아보았다. **대상 및 방법:** 유방초음파 및 유방 SPECT(Tc-99m tetrofosmin)를 시행하고 수술후 확진된 여자환자 40명(21명:악성종양, 19명:양성병변)의 영상자료를 분석하였다. 유방초음파영상을 컴퓨터분석 소프트웨어를 이용하여 병변의 경계를 분리한 후, 영상의 형태학적 특성들을 추출하였다. 초음파영상에서 추출된 형태학적 특성 중에서 감별능력이 있는 것으로 판단된 특성들을 골라 정량화하였다. 정량화된 형태학적 특성값들을 유방SPECT에서 구한 병변 대 반대측 유방의 방사능비와 판별분석에 의하여 결합하여 새로운 파라메터인 D-수치를 산출하였다. 유방SPECT의 병변 방사능비, 유방초음파 컴퓨터진단시스템의 악성확률 및 두가지를 결합한 D-수치에 대하여 수신자판단특성곡선(ROC curve) 분석을 이용하여 최적 판별 수치(cut-off value)를 구하고 이에 의한 유방암 진단의 예민도, 특이도 및 정확도를 계산하여 유방 SPECT과 초음파 컴퓨터진단시스템의 결합에 의한 진단성능을 기존의 유방 SPECT의 진단성능과 비교하였다. **결과:** ROC curve분석상에서 유방암 진단에 대한 성능은 유방초음파의 컴퓨터 분석시스템 및 유방SPECT 각각 모두 우수하였다(area under curve=0.831 and 0.846). 두 결과를 통계적인 방법으로 결합하였을 때 ROC curve분석의 area under curve는(0.860) 향상되었으나, 최적 판별 수치(cut-off value)에 의한 유방암 진단의 예민도, 특이도 및 정확도에는 통계적인 차이는 없었다. **결론:** 유방초음파의 컴퓨터분석시스템의 결과를 유방 SPECT에 적용하여 유방암의 진단성능을 향상시킬 수 있었지만 통계적으로는 유의하지 못하였다. 향후 추가적인 연구가 필요할 것으로 보인다.

References

1. Lim HW. National Cancer Screening Project in Korea. ***J Korean Society Breast Screening*** 2005;2:446.
2. Stewart SL, King JB, Thompson TD, Friedman C, Wingo PA. Cancer mortality surveillanceUnited States, 1990-2000. ***MMWR Surveill Summ*** 2004;53:1-108.

3. Kopans DB. The positive predictive value of mammography. ***AJR*** 1992;158:521-6.
4. Taillefer R. Breast scintigraphy. In: Ell PJ and Gambhir SS, editors. Nuclear Medicine in Clinical Diagnosis and Treatment. 3rd ed.. Edinburgh: Churchill Livingstone ; 2004. p. 17594.
5. Chen DR, Chang RF, Huang YL. Computer-aided diagnosis pplied to US of solid breast nodules by using neural networks. ***Radiology*** 1999;213:407-12.
6. Drukker K, Giger ML, Vybornyl CJ**,** Mendelson EB. Computerized detection and classification of cancer on breast ultrasound. ***Acad Radiol*** 2004;11:526-35.
7. Lee YH, Fam AT. An edge gradient enhancing adaptive order statistic filter. ***IEEE Trans Acoust Speech Signal Processing*** 1987;5:680-95.
8. Ostu N. A threshold selection method from gray-level histogram. ***IEEE Trans Syst Man Cybern*** 1979;9:62-6.
9. Hu MK. Visual Pattern Recognition by Moment Invariants. ***IRE Trans on Information Theory*** 1962;2:179-87.
10. Om KS, Moon WK. Method of searching nodule image independent of contrast and brightness and of determining malignancy or benignancy. Patent number 0461264, 2004.
11. Jackson VP. Management of solid breast nodules; What is the role of sonography? ***Radiology*** **1995;196;14-5.**
12. Erickson BJ, Bartholmai B. Computer-aided detection and diagnosis at the start of the third millennium. ***J Dig Imaging*** 2002;15:59-68.
13. Summers RM. Roadmaps for advancement of radiologic computer-aided detection in the 21st century. ***Radiology*** 2003;229:11-13.
14. Blickstein I, Goldchmit R, Starno SD, Goldman RD, Barzili N. Echogenicity of fibroadenoma and carcinoma of the breast. Quantitative comparison using gain-assisted densitometric evaluation of sonograms. ***J Ultrasound Med*** 1995;14: 661-64.
15. Huber S, Danes J, Zuna I, Teubner J, Medl M**,** Delorme S. Relevance of sonographic B-mode criteria and computer- aided ultrasonic tissue characterization in differential/ diagnosis of solid breast masses. ***Ultrasound Med Biol*** 2000; 26:1243-52.
16. Bongers V, Borel Rinkes IH, Sie-Go DM, Pijnappel R, de Hooge P and van Rijk PP. Detection of malignant breast tumors in dense breast tissue: results of Tc-99m tetrofosmin scintimammography related to surgery. ***Eur J Surg Oncol*** 1999;25:152-6.
17. Spanu A, Dettori G, Nuvoli G, Porcu A, Falchi A, Cottu P, et al. Tc-99m tetrofosmin SPECT in the detection of both primary breast cancer and axillary lymph node metastasis. ***Eur J Nucl Med*** 2001;28:1781-94.
18. buscombe JR, Cwikla JB, Holloway B, Hilson AJ. Prediction of the Usefulness of Combined Mammography and Scintimammography in Suspected Primary Breast Cancer Using ROC Curves. ***J Nucl Med*** 2001;42:3-8.
19. Bone B, Wiberg K, Szabo BK, Szakos A**,** Danielsson R. Comparison of Tc-99m Sestamibi Scintimammography and dynamic MR Imaging as adjuncts to mammography in the diagnosis of breast cancer. ***Acta Radiologica*** 2003;44:28-34.
20. Kupinski MA, Edwards DC, Giger ML, Metz CE. Ideal observer approximation using Bayesian classification neural networks. ***IEEE Trans Med Imaging*** 2001;20:886-99.